

# Identification of a Second Suspect via Stomach Contents at Autopsy

Lisa Pope

Forensic Analyst, Eugene Police Department, Forensic Evidence Unit,  
Eugene, Oregon, USA

---

## ABSTRACT

A case report describing the examination of stomach contents at the autopsy of a robber, who was shot and killed during the commission of his crime, which led to the identification of the second and outstanding robber. During autopsy, digested stomach contents gave the attending forensic analyst information regarding a possible location of two robbery suspects prior to committing their crime. This information led the analyst to a Wendy's fast food restaurant near the vicinity of the crime and video analysis from the restaurant's surveillance system provided investigators with the face of a known criminal they could identify.

**Keywords:** Autopsy, stomach contents, gastric contents, digestion rate, crime scene reconstruction, forensic science

---

---

## Introduction

Attention to detail plays an important role in crime scene reconstruction. Although long hours and aching bodies are usually synonymous with working major crime scenes, crime scene analysts must remain alert and attentive until their reconstruction, processing, and analysis is complete. This case study discusses how a nearly undigested french fry located within the stomach contents of a deceased robbery suspect lead to the identification of his accomplice through video surveillance at a local fast food restaurant.

The composition of the meal, the volume of the meal, as well as the individual foodstuffs

that comprise the meal have an affect on digestion rate. Less dense and less fibrous foods may begin to digest almost immediately; where more dense and fibrous foods take longer to break down. The volume of the foodstuffs ingested and how well they are broken apart prior to ingestion also affect digestion time. The physical breakdown of the foodstuffs is accomplished through mastication (chewing), the more thorough the mastication process, the more rapid the digestion. The typical gastric transit time of an "average" meal is estimated around two to three hours [1, 2].

---

## ARTICLE INFORMATION

Received: 05 March 2012

Revised: 03 April 2012

Accepted: 01 May 2012

---

Citation: Pope L. Identification of a Second Suspect via Stomach Contents at Autopsy. *J Assoc Crime Scene Reconstr.* 2012;18(2):13-15.

Author Contact:

[lisa.m.pope@ci.eugene.or.us](mailto:lisa.m.pope@ci.eugene.or.us)

---



## Case Background

On November 24, 2010 at 10:00pm in Eugene, Oregon, two armed subjects held up a Dutch Brothers coffee kiosk. Only one of the subjects approached the barista. The known subject was armed when he demanded and received money from the barista. He then demanded the barista to turn around, place his hands on the back of his head, and close his eyes. The barista, fearing for his life, drew his own firearm, resulting in an exchange of gun fire and the death of the known suspect. As the barista was unarming the downed and deceased suspect, a second subject appeared, causing an additional exchange of gun fire. According to the barista, this second outstanding subject fled the scene on foot.

Crime scene analysts for the Eugene Police Department Forensic Evidence Unit were assigned to process and reconstruct this crime scene. Based on the evidence at the scene and the barista's statements, the second outstanding subject quickly became the main focus of the investigation.

## Case Information and Investigation

The deceased subject was located on the back porch of the Dutch Brothers kiosk, with his feet lying just inside the open door frame. Lifesaving attempts had been made by responding medics; therefore the body had been moved prior to the crime scene analysts' arrival. The subject was wearing dark clothing which included multiple layers of shirts and jackets, and a brimmed stocking cap which had a possible bullet hole through the brim. A hood of one of the outer jackets was pulled up over the brimmed stocking cap. The subject was also wearing gloves, a backpack, and a handkerchief around his neck. He had a holster attached to his belt and hidden under the front part of his pants.

The subject's shirts were cut during lifesaving attempts by responding medics. There was at least one bullet wound to his chest. The subject's eyes were open, and there was red brown staining on his shirt, gloved right hand, and on the paper money lying around and near his left and right hands. There was also purged fluid and particulate matter around the subject's nose and mouth.

Fired bullets and bullet holes were located inside the kiosk and on the back porch next to the body. The bullet holes inside the kiosk were most likely from exchange of gunfire between the barista and the deceased subject. When the barista realized a second subject was present, he began to raise his weapon while firing. Two 9mm Luger and nine .40 caliber S&W cartridge cases were recovered from inside the kiosk and the back porch. Forensic analysts discovered that the surveillance system at the coffee stand had not been working for quite some time and other nearby surveillance cameras did not have footage that showed the incident.

The lead crime scene analyst attended the autopsy of the deceased the following day. The medical examiner was to determine the six bullet paths through the body and recover any bullet or other evidence inside the body.

Examining gastric contents at autopsy can provide valuable information. A medical examiner can estimate the time of death, and time of last meal, based on the appearance of the digesting food.

During this particular autopsy, examination of the stomach contents by the medical examiner revealed pieces of ground beef, pieces of cheese, and half inch long pieces of bacon. The medical examiner identified these stomach contents as a bacon cheeseburger. He also noticed that the meal appeared to contain partially digested french fries. It was noted by the forensic analyst that one of the french fries was fairly undigested and appeared nearly whole, and asked to take a closer look. At the request of the forensic analyst, the medical examiner estimated the food was most likely consumed within an hour of the robbery. Upon close examination, the forensic analyst realized the partially digested fry appeared to be consistent with Wendy's Restaurant fast food french fries. She realized it was consistent with a Wendy's french fry because at that time they were thicker than the other fast food french fries in the vicinity of the crime scene. The forensic analyst knew there were fast food restaurants within city blocks of the crime scene and the one nearest the Dutch Brothers kiosk was a Wendy's Restaurant.

The forensic analyst immediately notified detectives and recommended that they contact the Wendy's regarding surveillance footage. Detectives found that the footage from the



restaurant clearly contained images of both robbery suspects. The footage showed the first suspect trying on his mask, which was a handkerchief around his neck that he was using to cover his face. This footage was used to identify his accomplice and led to the second subject's arrest.

## Conclusion

This case is a good example of why attention to detail and placing evidence in context is an important quality of a crime scene analyst. Though many may have felt that the partially digested stomach contents of a subject had little probative value, by associating this with the known facts of the case, the area in which the crime was committed and the scene as a whole, the forensic analyst was able to associate it to a specific Wendy's restaurant product.

In this case, a bacon cheeseburger and fries were located in the stomach contents of the deceased. Furthermore, the death was sudden and unexpected versus prolonged and stressful, therefore an undigested french fry located inside the gastric contents of the deceased was consistent with a consumption time within an hour prior to death [1]. This information aided

in the development of logical investigative leads and direction by reconstructing the likely sequence of events made by the perpetrators in preparation for committing the crime. This resulted in valuable video evidence showing the identity of the second outstanding suspect being retrieved by law enforcement.

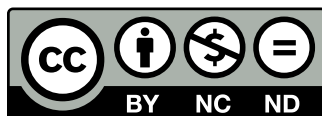
Using the totality of information and the crime scene analyst's forensic expertise, a reconstruction of events can be completed, improving the chances of solving crimes and successfully prosecuting criminals.

## Acknowledgements

The author would like to thank Dr. Dan Davis, the Medical Examiner for the Eugene Medical Examiner's Office, and Jason Petersen, the Forensic Laboratory Supervisor of the Eugene Police Department.

## References

- [1] Saukko P, Knight B. Knight's Forensic Pathology. 3rd ed. New York (NY): Oxford University Press; 2004.
- [2] DiMaio V, DiMaio, D. Forensic Pathology. 2nd ed. Boca Raton (FL): CRC Press; 2001.



Copyright: © 2012 Lisa Pope. Copyright for this article is retained by the author, with publication rights granted to the Association for Crime Scene Reconstruction. This is an Open Access article distributed under the terms of the Creative Commons Attribution-Noncommercial-No Derivatives License (<http://creativecommons.org/licenses/by-nc-nd/3.0/>) which permits unrestricted noncommercial use, distribution, and reproduction, provided the original work is properly cited and not changed in any way.



