

# The Survival of Neat and Cleaned Blood after the Application of Wallpaper

Ivanie Stene<sup>1</sup> and Tom Adair, MS

<sup>1</sup> Senior Criminalist, Westminster Police Department, Westminster, CO, USA

---

## ABSTRACT

We report on a study in which neat (undiluted) and cleaned bloodstains were covered with commercial wallpaper in order to test methods of discovery and recovery of said stains. Cleaned and camouflaged (covered) bloodstains pose significant challenges to the crime scene reconstructionist. Criminals may employ a variety of methods to destroy bloodstain evidence from a simple cleaning with water to extreme measures such as covering the cleaned areas with paint or wallpaper. This study supports the conclusion that neat and cleaned bloodstains are very difficult to detect through wallpaper but may be detected once the wallpaper is removed.

**Keywords:** Blood detection, luminol, leucocrystal violet, crime scene reconstruction, forensic science

---



---

## ARTICLE INFORMATION

Received: 6 May 2012

Revised: 31 July 2012

Accepted: 3 August 2012

Citation: Stene I, Adair T. The Survival of Neat and Cleaned Blood after the Application of Wallpaper. *J Assoc Crime Scene Reconstr.* 2012;18(3);21-28.

Author Contacts:  
istene@cityofwestminster.us,  
sof32@comcast.net

---



---

## Introduction

Crime scene analysts sometimes encounter blood evidence that has been cleaned, camouflaged, or both. Dilution or destruction of bloodstains by natural or deliberate acts can severely complicate the reconstruction process. The most destructive of these acts is the deliberate cleaning of bloodstains with chemical agents such as bleach. Several authors have written about the detection of concealed or camouflaged bloodstains and the effects of various environmental and cleaning processes affecting our abilities to detect them [1-14]. When considering the cleaning process

there are several factors which influence the “effectiveness” of the cleaning: blood volume, receiving surface (porous or non-porous), cleaning agents used, and duration or complexity of cleaning.

For example, Adair and Shaw [8] found that bloodstain patterns developed on washed clothing (up to five laundry cycles) remained relatively unchanged (morphology) relative to the neat bloodstain patterns prior to washing. In contrast, Creamer et al. [11] discovered that bloodstains cleaned on nonporous surfaces generally did not retain their original shape or form. Aside from cleaning, criminals may also make efforts to





▲  
Figure 1: Painted wallboards prior to blood staining.

conceal the cleaned area through such methods as new carpeting, paint, or wallpaper.

### Experimental Design

This project was designed to test the effectiveness of detecting and restoring both neat and cleaned bloodstains covered with wallpaper. Two testing walls were created by affixing a 24 x 24 x 1/2 inch gypsum wallboard to a 2 x 4 inch wood stud

One of the two walls was designated for cleaning while the other wall was to be left neat before applying the wallpaper. After approximately one hour of drying, one wall was wiped down with a clean cotton cloth soaked with warm water. The bloodstains were thoroughly wiped until only a faint yellow discoloration was seen on the paint (Figure 4). Both walls were allowed to dry under a fume hood for 4 days before applying the wallpaper.

Two paper affixing methods were used for each wall. One half of each wall was covered with a paper (geometric pattern) designed to be affixed with an adhesive. For this experiment, Zinsser DIF wallpaper adhesive was used to affix the paper. The second half of each wall was covered with a paper (scroll pattern) affixed with warm water (Figure 5). Following the instructions for the wallpaper, the scroll-patterned wallpaper was held under warm water for approximately 30 seconds and

▶  
Figure 2 (left): Wallboard with bloodstains prior to wallpaper application.



▶  
Figure 3 (right): Wallboard with bloodstains prior to wallpaper application.



▶  
Figure 4: Wallboard after cleaning blood with warm water.



frame. The walls were painted with two coats of Glidden white colored interior latex semi-gloss paint and allowed to dry for three weeks prior to testing (Figure 1). Horse blood was used for all testing in this study. A variety of bloodstain patterns to include spatter, transfer staining (shoe impressions and fingerprint impressions), drip stains, and projected blood, were applied to both walls. Several areas were allowed to dry for approximately ten minutes before a clean dry cloth was wiped across part of the bloodstained area to create a “perimeter stain” (Figure 2 & Figure 3).



◀ Figure 5: Wallboards after application of wallpaper.

then applied to the walls. The wallpapers were allowed to dry on the walls for approximately 2 weeks prior to any further examination.

A visual inspection of the walls was performed after the 2-week period, which revealed an interesting condition: The scroll-patterned wallpaper on the wall containing the neat blood displayed some areas of bleed-through. At the time of purchase, the scroll-patterned wallpaper was folded over numerous times and packaged in plastic wrap. Some of the bleed-through areas were located in the folds of the wallpaper, while the other bleed-through areas were randomly located throughout the paper (Figure 6). An examination later revealed that the bleed-through areas did not correspond with the original pattern types of the bloodstains.

### Non-invasive Examination

The first phase of the experiment was to test the feasibility of non-destructive methods of detection. This included a visual inspection of the walls under normal light, followed by an examination with ultraviolet light. Two different Alternate Light Source (ALS) units were used for this phase of the analysis. A SPEX CS16-500 and a Lynn Peavey Ultralite ALS were used on all available wavelengths with the authors wearing yellow, orange, and red goggles for all available wavelengths. Both walls were examined using these ALS devices. A reaction was not visible using the ALS devices. Had a reaction occurred, the bloodstains would appear darker than their original color, as the

bloodstains absorb the light from the ALS. One small area (approximately 1cm<sup>2</sup>) on one wall did fluoresce a milky white color at 465nm but was thought to be from a patent finger mark, and appeared to be on the surface of the paper, not underneath. These inspections were followed by swabbing the paper surfaces for testing with the phenolphthalein reagent. The swabs yielded negative results from phenolphthalein testing.

### Blood Reagent Testing

The next phase of the experiment included the application of two types of blood detecting reagents to the exterior surfaces of both types of wallpaper to both the neat and clean wallboards. The walls were divided into two halves, each section containing both types of

Figure 6: Area of blood bleed-through on wallpaper.





▲ Figure 7: False-positive reaction to luminol reagent on wallpaper.

▶ Figure 8: False-positive luminol reaction on control wallpaper sample.

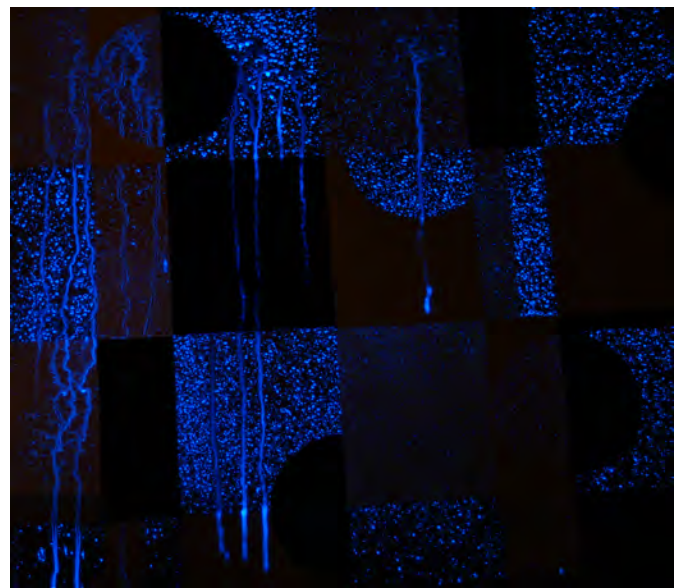
wallpaper. This allowed for the testing of each reagent on each brand of wallpaper covering both cleaned and neat bloodstains. The other portion of each wall was protected with plastic sheeting to prevent any reagent contact. For this experiment, the authors used commercially available kits of the blood reagents luminol (5-amino-2,3-dihydro-1,4-phthalazinedione, sodium carbonate, sodium perborate, and water) and leuco crystal violet (LCV) (5-sulfosalicylic acid, hydrogen peroxide, and water).

## Results

The LCV was mixed in a spray bottle and applied to one section of each wall having each type of wallpaper. Reagent viability was verified with known blood samples located on the wall frames. The wallpaper containing the geometric patterns produced a negative result for the presence of blood, but the wallpaper containing the scroll pattern produced a positive result in a few small areas. The reaction appeared to only be located in a few of the folds on the wallpaper, where there was also a visible appearance of blood. Interestingly, other areas of visible blood staining in other folds did not have a strong reaction with the LCV.

The application of the luminol reagent produced some surprising results. The reagent was mixed in a spray bottle and applied to the previously protected section of each wall containing both types of wallpaper. The wallpaper containing the geometric patterns

produced a strong and immediate luminescence, but only in certain colored “boxes” of the wallpaper pattern (Figure 7). The authors hypothesized that one of two reactions was happening. One possibility is that the reagent was reacting with the underlying blood and the negative, or non-reactive, portions of the surrounding paper contained properties masking this reaction. The second possibility was that the reaction was a false positive. The authors contacted a senior technician at the manufacturing plant producing that wallpaper, however he was unable to provide an explanation for the observed reaction. The authors then tested a clean section of wallpaper from the same roll of wallpaper used in the testing. This paper had no previous known exposure to blood. After applying the luminol reagent to the paper, the same colored boxes reacted with a positive luminescence (Figure 8). The authors were unable to determine what properties in the ink or paper contributed to the false positive reaction.



The wallpaper containing the scroll pattern produced a negative result for the presence of blood in the areas of the known bloodstains. Three strips of the wallpaper containing the scroll pattern were applied to half of each wallboard. A positive reaction did occur with the luminol in the seams of the wallpaper. The authors concluded that the reaction was most likely from a small amount of blood which had seeped out of the seam when the wallpaper was applied with the water.



◀ Figure 9: Weak reaction of LCV reagent to wallboard after removing wallpaper.

## Wallpaper Removal

Following reagent testing the authors made attempts to remove the wallpaper in an effort to determine if additional testing could be done on the underlying bloodstains. The authors also wanted to document the condition of the bloodstains and their survival following the application of wallpaper. The wallpaper was removed with two methods. One was the application of a sponge soaked with warm water to loosen the adhesive. The other method was the use of a surgical scalpel to reflect the paper away from the wall in a manner similar to removing an animal hide. Ultimately, both methods were necessary to fully remove both wallpapers.

The neat bloodstains retained a surprising amount of their original shape and volume under the geometric wallpaper affixed with adhesive (Table 1). The authors could easily see and measure various blood drops as well as the partial footwear impression. Mirror impressions of the bloodstains were also visible on the backside of the wallpaper. Swabbing of selected bloodstains on the wall were tested with phenolphthalein and yielded positive results. The backside of the geometric-patterned paper (affixed with adhesive) also yielded positive phenolphthalein results. The partial fingerprint impression was not visible.

The neat bloodstains under the scroll-patterned paper affixed with water did not retain much detail. The stains had a dull grey appearance. While several bloodstains were visible, their shape and directionality was obscured through dilution of the blood with the water during the application of the wallpaper. Bloodstains were not visible on the back side of the wallpaper. Positive phenolphthalein results were obtained from swabbings of both the wall and the backside of the wallpaper.

The wall containing the washed bloodstains was then examined. The wallpapers were removed in the same manner as the other wall. There was no visible blood staining on the wall or on the back of the wallpapers. Random swabbings of the wall and back of the wallpapers

◀ Figure 10 (left): Luminol reaction to exposed wallboard after wallpaper removal.

Figure 11 (below): Corresponding area of blood staining prior to cleaning and wallpaper application.



Table 1 ►











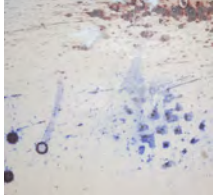

|  | Wallboard - Neat Blood  | Wallboard - Cleaned Blood   |
|--|---|---|
| Bloodstain Patterns Prior to Wallpaper / Prior to Cleaning |  |  |
| Application of Wallpaper                                   |  |  |

Table 2 ►

|                        | Wallboard - Neat Blood  | Wallboard - Cleaned Blood  | Wallboard - Neat Blood (After Removal of Wallpaper)                                   | Wallboard - Cleaned Blood (After Removal of Wallpaper)                                |
|------------------------|---|--|---|---|
| Alternate Light Source |  | Negative Results   | Not Tested  | Not Tested  |
| Luminol                |  |  |  |  |
| LCV                    |  | Negative Results   |  |  |

were tested with phenolphthalein with negative results. One very small area of slight discoloration was seen on the wall. The small area did test positive with phenolphthalein. One half of the wall was tested with LCV with poor results. Some weak uniform reaction did occur (Figure 9), but did not correspond to the original shape or distribution of bloodstains prior to cleaning.

The other half of the wall was treated with luminol. There was a strong and immediate chemiluminescence, however the reaction was fairly uniform and did not correspond well with the blood staining prior to cleaning (Figures 10 & 11). Luminol was also applied to the side already treated with LCV yielding similar results (Table 2).

## Conclusion

Criminals may take steps to conceal or camouflage blood evidence following the commission of a crime. Some criminals may go beyond simple cleaning to include covering the bloodstained area with wallpaper. This study was designed to investigate two important issues. The first was to test the survivability of both cleaned and neat bloodstains on painted walls following the application of wallpaper. The second issue was to investigate several methods of detecting and documenting the presence and investigative value of those bloodstains.

In this study, the authors were largely unable to detect the latent and patent bloodstains under the wallpaper by either visual or chemical means. The one exception was a small amount of blood found at the folds and seams of the scroll-patterned wallpaper. These conditions may not be present when other types of wallpapers (rolls not sheets) are used. While not applicable to all types of wallpapers, our results suggest that investigators should expect the necessity to remove wallpapers at a crime scene if they believe there are bloodstains underneath.

The blood reagents luminol and LCV were selected for this study due to their common use among many bloodstain pattern analysts and crime scene reconstructionists. One finding of note in this study was the false

positive reaction of luminol to properties of one of the wallpapers tested. The percentage of commercially and historically available wallpapers exhibiting these properties remains unknown, so investigators should consider the possibility of a false positive reaction during crime scene processing.

This study indicates that manufacturer recommended methods for paper removal are acceptable. Our study suggests that commercial wallpaper adhesives may do less damage to neat bloodstains than the warm water soaking method for affixing wallpaper. Additionally, some bloodstains may be retained on the backside of the wallpaper, so these sheets should not be discarded until all reasonable testing procedures have been exhausted. Our findings indicate that some neat bloodstains may retain enough detail (after covering) to be useful for measurement and have value for reconstruction. This included the survival of partial footwear impressions and even the potential to develop a partial fingerprint impression with LCV.

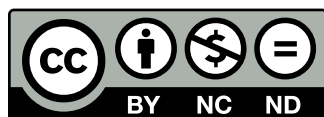
The survival of bloodstain evidence seems dependant upon a number of factors including the quality of the original stain, physical properties of the wallpaper, and methods of application, and methods used to clean any bloodstains prior to covering with wallpaper. The cleaning methods employed in this study consisted of using hot water. No chemical cleaners were used, but we hypothesize that the use of such products would further complicate detection and recovery efforts. It is our hope that other researchers will expand upon this study to test other variables and conditions of camouflaged and covered bloodstains.

## References

- [1] Vandenberg N, van Oorschot R. Locating Blood and Saliva Stains Using Polilight. Poster presented at: 17th International Symposium on the Forensic Sciences, Australian and New Zealand Forensic Science Society; 2004. Available from: <http://www.anzfss2004.org.nz/cgi-bin/ViewAbstracts.cgi?paperid=178> (inactive link).



- [2] Ray B. Use of Alternate Light Sources for Detection of Body Fluids. *J Southwest Assoc Forensic Sci.* 1992;14(1):30-33.
- [3] Waldoch TL. Chemical Detection of Blood After Dilution by Rain Over a 72 Day Period. *J Forensic Ident.* 1996;46(2):173-177.
- [4] Alioto D, director. Lizzie Borden had an Axe [television program]. USA: Morningstar Entertainment; 2004.
- [5] Specht W. Die Chemiluminesenz des Hamins, ein Hilfsmittel zur Auffindung und Erkennung foensisch wichturger Blutspuren [The Chemiluminescence of Hemin as a means of finding and recognizing blood traces of forensic importance]. *Angew Chem.*1937;50:155-157. German.
- [6] Howard MC, Nesson M. Detecting Bloodstains Under Multiple Layers of Paint. *J Forensic Ident.* 2010;60(6):682-703.
- [7] Culen S, Otto A, Cheetham PN. Chemical Enhancement of Bloody Footwear Impressions from Buried Substrates. *J Forensic Ident.* 2010;60(1):44-83.
- [8] Adair T, Shaw R. Enhancement of Bloodstains on Washed Clothing Using Luminol and LCV Reagents. *LABPA News.* 2005;21(4):4-10.
- [9] Bodziak WJ. Use of Leuco Crystal Violet to Enhance Shoe Prints in Blood. *Forensic Sci Int.* 1996;82:45-52.
- [10] Quickenden TI, Ennis CP, Creamer JI. The Forensic Use of Luminol Chemiluminescence to Detect Traces of Blood Inside Motor Vehicles. *Luminescence.* 2004;19:271-277.
- [11] Creamer JI, Quickenden TI, Crichton LB, Robertson P, Ruhayel RA. Attempted Cleaning of Bloodstains and its Effect on the Forensic Luminol Test. *Luminescence.* 2005;20(6):411-413.
- [12] DeHaan DJ, Clark JD, Spear TF, Oswald R, Barney SS. Chemical Enhancement of Fingerprints in Blood: An Evaluation of Methods, Effects on DNA, and Assessment of Chemical Hazards. Available from: [www.latent-prints.com/cac\\_blood.htm](http://www.latent-prints.com/cac_blood.htm).
- [13] Gifford WDL. Bloodstain Survival in Water. *LABPA News.* 1999; 15(2):1-6.
- [14] Quickenden TI, Cooper PD. Increasing the Specificity of the Forensic Luminol Test for Blood. *Luminescence.* 2001; 16:251-253.



Copyright: © 2012 Ivania Stene and Tom Adair. Copyright for this article is retained by the author, with publication rights granted to the Association for Crime Scene Reconstruction. This is an Open Access article distributed under the terms of the Creative Commons Attribution-NonCommercial-No Derivatives License (<http://creativecommons.org/licenses/by-nc-nd/3.0/>) which permits unrestricted noncommercial use, distribution, and reproduction, provided the original work is properly cited and not changed in any way.